

VIDEOS IN CLINICAL MEDICINE
SUMMARY POINTS

Needle Aspiration of Primary Spontaneous Pneumothorax

Mathieu Pasquier, M.D., Olivier Hugli, M.D., and Pierre-Nicolas Carron, M.D.

The following text summarizes information provided in the video.

OVERVIEW

Primary spontaneous pneumothorax occurs in patients without clinically apparent lung disease or trauma.¹⁻⁵ Observation may be the only requirement for patients with small primary spontaneous pneumothoraxes.⁵ For a large pneumothorax or one that causes clinically significant breathlessness, active intervention is required.⁴ This intervention may involve simple aspiration, the placement of a chest tube,^{1,2} or needle aspiration. Needle aspiration is considered to be as effective and safe as chest-tube thoracostomy for the management of primary spontaneous pneumothorax.²⁻⁴ Needle aspiration results in less discomfort and pain, a shorter hospital stay, and fewer hospital admissions than does chest-tube thoracostomy.²⁻⁴ Emergency-department physicians should be familiar with this technique and be able to explain it to patients as part of the decision-making process involved in determining the best treatment.³ This supplement reviews the information provided in the video on the techniques and equipment required to perform needle aspiration of primary spontaneous pneumothorax in adults. Although needle aspiration may also be indicated for select patients with secondary pneumothorax, its use in patients with this condition is not addressed here or in the video.

From the University Hospital of Lausanne, Lausanne, Switzerland. Address reprint requests to Dr. Carron at Emergency Service, University Hospital of Lausanne, BH06, 1011 Lausanne CHUV, Switzerland, or at Pierre-Nicolas-Carron@chuv.ch.

N Engl J Med 2013;368:e24.

DOI: 10.1056/NEJMvcm1111468

Copyright © 2013 Massachusetts Medical Society.

INDICATIONS

Needle aspiration is appropriate for patients with a first episode of primary spontaneous pneumothorax. Patients should have no evidence of underlying lung disease but should have either shortness of breath or a pneumothorax with a rim of air measuring at least 2 cm when assessed at the level of the hilum.⁴

CONTRAINDICATIONS

Needle aspiration is contraindicated when a patient has traumatic pneumothorax, pneumothorax in each lung, tension pneumothorax, hemodynamic instability, underlying pulmonary disease, a history of recurrent pneumothorax, or a bleeding disorder. An age older than 50 years is a relative contraindication, because the procedure is less likely to be successful in patients in this age group.^{1,4,5}

EQUIPMENT

Different types of catheters can be used to perform needle aspiration, and you should be familiar with the specific devices available at your institution. The procedure requires a 16-gauge or 18-gauge over-the-needle catheter, tubing with a three-way stopcock, and a 50-ml or 60-ml syringe. To administer a local anesthetic agent, you will need 1% or 2% lidocaine, a 10-ml syringe, and one small-gauge needle (size 25); for anesthetizing deeper layers of tissue, you will also need one larger-gauge needle (size 22). You will also need sterile gloves, a protective or sterile gown, a face

mask, chlorhexidine or another antiseptic solution, a sterile preparation kit, and sterile drapes.

PATIENT PREPARATION

To prepare the patient, explain the procedure, confirm the patient's identity, and obtain written informed consent. You should also verify the absence of contraindications, confirm that the patient has no allergy to lidocaine, and verify whether the pneumothorax is on the right or the left side. Place the patient in a semisupine position (with the torso at an angle of 30 to 45 degrees) to allow the air to collect at the apex of the lung. Administer oxygen and monitor the oxygen saturation of the arterial blood with pulse oximetry. Heart rate and blood pressure should also be monitored, and an intravenous catheter should be in place. The patient should be provided with a face mask.

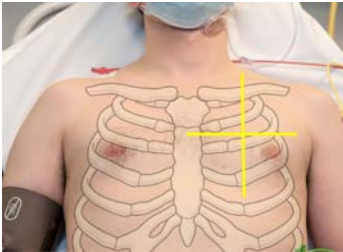


Figure 1. Site of Needle Insertion.

The preferred location for placement of a needle for aspiration of pneumothorax is the second intercostal space at the midclavicular line, on the side with the pneumothorax.

LOCATING LANDMARKS

The preferred location for placement of a needle for aspiration of pneumothorax is the second intercostal space at the midclavicular line, on the side with the pneumothorax. Begin by locating the second and third ribs. The second rib can be felt just below the collar bone. The second intercostal space is the area between the second and third ribs. Next, identify the middle of the clavicle and the midclavicular line. The intersection of the midclavicular line and the second intercostal space is the correct place to insert the needle for aspiration of pneumothorax (Fig. 1). A skin-marking pen can be used to mark the insertion site.

PROCEDURE

Put on the face mask, the protective or sterile gown, and the sterile gloves. Use chlorhexidine or another antiseptic solution to clean the patient's skin, and then position the sterile drape. Aspirate lidocaine into the 10-ml syringe. Using the 25-gauge needle, inject a wheal of lidocaine at the superior edge of the third rib, at the midclavicular line. Switch to a 22-gauge needle and anesthetize the deeper tissue layers by inserting the needle perpendicular to the skin. Always aspirate the site before injecting the anesthetic, to make sure the needle has not entered a blood vessel.

With the needle positioned just over the top of the third rib, advance it in the direction of the pleural space. Placing the needle just above the third rib will prevent injuries to the intercostal vessels and nerves, which lie just below the rib. Once you have inserted the needle through the intercostal space, continue to aspirate slightly. When you penetrate the pleural space, air bubbles will appear as you aspirate (Fig. 2). Before you remove the needle, note the depth of the penetration. You will use the depth as a reference point when you insert the over-the-needle catheter.

Connect the over-the-needle catheter to the 10-ml lidocaine syringe, which should be partially filled with the remainder of the local anesthetic. Using the same landmarks that you used for the local anesthetic, slowly advance the needle in the direction of the pleural space while continuing to aspirate with the syringe. Again, when the needle penetrates the pleural space, air bubbles will appear in the syringe. At this time, advance the needle by a few more millimeters to allow the catheter tip to fully penetrate the pleural space. Remove both the catheter needle and the 10-ml syringe as the patient exhales or coughs. Quickly obstruct the opening of the catheter with your finger to prevent the entry of additional air into the pleural space.

Attach the tubing with the three-way stopcock to the catheter, and use the 50-ml or 60-ml syringe to gently aspirate the air from the pleural space (Fig. 3). Manipulation of the three-way stopcock requires close attention, since any opening to the

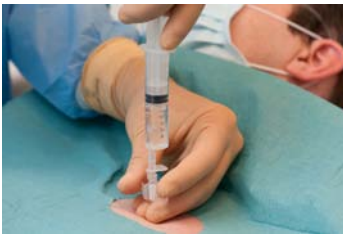

Figure 2. Confirmation of Penetration of Pleural Space.

The appearance of air bubbles in the syringe, which is partially filled with the local anesthetic, indicates that the catheter has penetrated the pleural space.

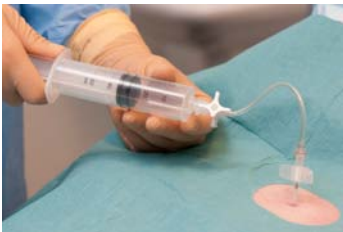

Figure 3. Aspiration of Air from a Pneumothorax.

After air is aspirated from a pneumothorax, it is returned to the ambient air through the side port of a three-way stopcock.

ambient air can lead to air entrapment in the pleural space and failure of the procedure. When manipulating the stopcock, be sure that the pleural space is never open to the environment. Return the air through the side port into the ambient air and measure the volume of the air that is aspirated by counting the number of syringes you evacuate. The evacuation of more than 2.5 liters is an indication that there may be an air leak, and the procedure should be stopped.^{1,4,5} Continue manual aspiration until you cannot aspirate any more air. Remove the catheter and put a sterile dressing on the site of insertion.

A postprocedural chest radiograph should be obtained with the patient in an upright position. When needle aspiration is successful, the patient's symptoms will improve, and only minimal residual pneumothorax — or no pneumothorax — should be present on the chest film.^{3,6} Most patients are ready for discharge 6 hours after the procedure, provided that a second postprocedural chest radiograph shows no recurrence of the pneumothorax.^{1,5,6} The time of patient discharge will vary according to the institution.

COMPLICATIONS

Complications from needle aspiration of primary spontaneous pneumothorax may include localized subcutaneous emphysema, infection, lung laceration, air embolism, or bleeding. You can minimize the risk of bleeding by placing the catheter at the intercostal space just above the third rib, thereby preventing injuries to the intercostal vessels. Technical failure may occur if you cannot reach the pleural space — if the catheter is too short, for instance. This problem most often arises in patients who are very muscular or obese. Aspiration of more than 2.5 liters of air may indicate the presence of a persistent air leak, for which the placement of a chest tube should be considered.^{1,4,5}

SUMMARY

Needle aspiration is an alternative treatment to the placement of a chest tube for patients with a first episode of primary spontaneous pneumothorax. A careful preprocedural evaluation is needed to be certain that there are no contraindications. All patients should be monitored closely during the procedure. After the anatomical landmarks have been identified and the local anesthetic agent has been administered, the intrapleural air can be evacuated through a large-bore catheter. The success of the procedure is confirmed by clinical improvement and by a chest film showing no or minimal residual pneumothorax.

No potential conflict of interest relevant to this article was reported.

Disclosure forms provided by the authors are available with the full text of this article at NEJM.org.

REFERENCES

1. Sahn SA, Heffner JE. Spontaneous pneumothorax. *N Engl J Med* 2000;342:868-74.
 2. Wakai A, O'Sullivan RG, McCabe G. Simple aspiration versus intercostal tube drainage for primary spontaneous pneumothorax in adults. *Cochrane Database Syst Rev* 2007;1:CD004479.
 3. Zehtabchi S, Rios CL. Management of emergency department patients with primary spontaneous pneumothorax: needle aspiration or tube thoracostomy? *Ann Emerg Med* 2008;51:91-100. [Erratum, *Ann Emerg Med* 2008;51:309.]
 4. MacDuff A, Arnold A, Harvey J, BTS Pleural Disease Guideline Group. Management of spontaneous pneumothorax: British Thoracic Society Pleural Disease Guideline 2010. *Thorax* 2010;65:Suppl 2:ii18-ii31.
 5. Kosowsky JM. Pleural disease. In: Marx JA, ed. *Rosen's emergency medicine: concepts and clinical practice*. 7th ed. Vol. 1. Philadelphia: Mosby, 2010:939-43.
 6. Ho KK, Ong ME, Koh MS, Wong E, Raghuram J. A randomized controlled trial comparing minichest tube and needle aspiration in outpatient management of primary spontaneous pneumothorax. *Am J Emerg Med* 2011;29:1152-7.
- Copyright © 2013 Massachusetts Medical Society.