

VIDEOS IN CLINICAL MEDICINE

Ultrasound-Guided Internal Jugular Vein Cannulation

Rafael Ortega, M.D., Michael Song, M.D., Christopher J. Hansen, M.A.,
and Paul Barash, M.D.

OVERVIEW

Traditionally, internal jugular vein cannulation has been performed with the use of external anatomical landmarks and palpation to guide insertion of the needle into the vessel. However, depending on the operator's experience and the patient's anatomy, this procedure may be difficult or unsuccessful. Over the past decade, the increased use of ultrasonography to guide internal jugular vein cannulation has improved success rates, reduced the time required to perform the procedure, and reduced complications.¹⁻³

INDICATIONS

Ultrasound-guided internal jugular vein cannulation is performed when direct access to the central circulation is needed. Access may be required for a variety of purposes, including monitoring central venous pressure, inserting pulmonary-artery catheters, administering intravenous therapeutic agents and nutrition, performing hemodialysis, and placing cardiac pacemakers.

CONTRAINDICATIONS

General contraindications to internal jugular vein cannulation include infection of the placement site and suspected pathologic conditions affecting the internal jugular vein or the superior vena cava (such as occlusion caused by coagulopathy). Caution should be used when the landmarks have been distorted by trauma or when other anatomical anomalies are present. Be careful when using this procedure in patients who have prior injury to the internal jugular vein, have very small internal jugular veins, or are morbidly obese. In these circumstances, alternative sites should be considered; however, use of the femoral vein is associated with a higher incidence of infection and therefore should be avoided.

Ultrasonography is a noninvasive, nonionizing form of imaging that is safe for use in patients of all ages and in women who are pregnant. There are no contraindications specific to the use of ultrasound guidance during internal jugular vein cannulation.

EQUIPMENT

Central venous catheters vary in size, length, and number of infusion ports. The choice of catheter depends on the clinical circumstance. Packaged central venous catheterization kits are commercially available. Kits may include drapes, disinfectant sponges, gauze pads, sutures with needles, a guidewire, a scalpel, a vein dilator, a penetration syringe, a guide syringe, an anesthetic syringe, and 1% or 2% lidocaine anesthetic solution. Sterile gloves, eye protection, a gown, a surgical cap, a mask, and a full-size sterile drape are also required.

From the Department of Anesthesiology, Boston Medical Center, Boston (R.O., M.S., C.J.H.); and the Department of Anesthesiology, Yale School of Medicine, New Haven, CT (P.B.). Address reprint requests to Dr. Ortega at the Department of Anesthesiology, Boston Medical Center, 88 E. Newton St., Boston, MA 02118, or at rortega@bu.edu.

N Engl J Med 2010;362:e57.

Copyright © 2010 Massachusetts Medical Society.

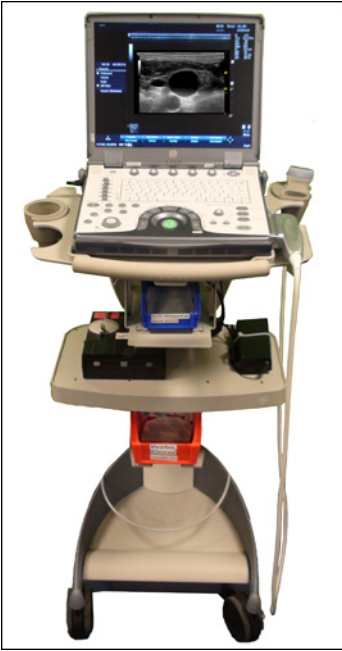

Figure 1. Ultrasound Machine with Transducer.

Ultrasound machines with linear-array, high-resolution vascular transducers are preferred for this procedure (Fig. 1). You will also need sterile transduction gel, an acoustically transparent sterile transducer sheath, and sterile rubber bands or clips to secure the sheath around the transducer.

PREPARATION

When possible, explain the procedure to the patient and obtain written informed consent. Potential complications such as infection and bleeding should be discussed. Conduct a procedural time-out and review a checklist before performing the procedure. Maintain continuous electrocardiographic and pulse-oximetry monitoring throughout the procedure.

POSITIONING

Place the patient in the supine position. If the central venous pressure is not elevated, place the patient in the Trendelenburg position to increase jugular filling and to reduce the possibility of air embolism. Caution is advised when placing patients with high intracranial pressure or congestive heart failure into this position, since it may exacerbate these conditions. Rotate the patient's head slightly to the contralateral side of the chosen site. Minimizing head rotation makes it less likely that this positioning will cause the common carotid artery to lie posterior to the internal jugular vein.⁴ Cannulation of the right internal jugular vein is generally preferred to cannulation of the left vein, because it provides more direct access to the right atrium, avoids the thoracic duct, reduces procedure time, and is associated with fewer complications.

ANATOMICAL LANDMARKS

The two heads of the sternocleidomastoid muscle and the clavicle form a triangle at the anterior neck. The internal jugular vein may be accessed within this triangle, approximately 2 to 3 cm above the clavicle (Fig. 2).

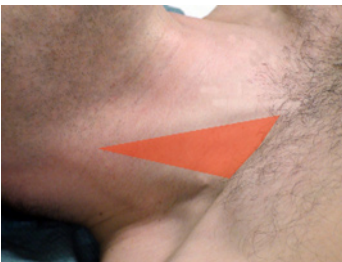

Figure 2. Triangle Delimited by the Two Heads of the Sternocleidomastoid Muscle and the Clavicle.

ULTRASOUND SURVEY

Variations in external landmarks and internal anatomy can make landmark-guided cannulation challenging. Ultrasound guidance minimizes the incidence of possible complications arising from these difficulties and permits visualization of the anatomy of the internal jugular vein and neighboring structures, particularly the carotid artery. The use of ultrasonography also contributes to shorter procedure times and permits confirmation of the patency of the internal jugular vein before cannulation is attempted. These benefits allow for a decreased number of needlesticks and reduce the propensity for infection.⁵

Although ultrasonography facilitates cannulation of the internal jugular vein, knowledge of the landmark technique is necessary. Ultrasonography should be seen as complementary to the landmark approach.

Before starting the procedure, perform an ultrasound survey to assess the location and patency of the internal jugular vein and to evaluate the neck anatomy. Position the transducer so that the resulting image on the screen correlates with the orientation of the anatomy. Place the probe parallel and cephalad to the clavicle and along the sternocleidomastoid muscle; the common carotid artery and the internal jugular vein should be easy to identify (Fig. 3). The common carotid artery will be pulsating; it is difficult to compress. The internal jugular vein will be larger and nonpulsating and is easily compressed. Ensure that the internal jugular vein is patent by gently compressing it with the transducer — slight pressure is sufficient to collapse the lumen of the internal jugular vein. You may position the

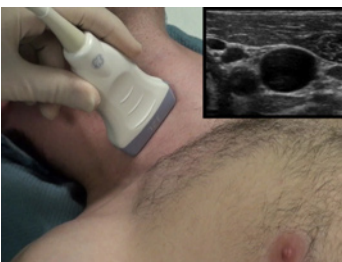

Figure 3. Ultrasound Transducer and Resulting Image.

transducer to provide either a cross-sectional or a longitudinal view. Placing the transducer in a standardized orientation will facilitate interpretation of the resulting images when you perform the procedure.

In the longitudinal view, the large vessels and needle are parallel to the ultrasound beam. In this view, the entire shaft and tip of the needle, as well as the course of a single vessel, can be visualized. In the transverse approach, the anatomy and needle are perpendicular to the ultrasound beam. Structures are visualized in cross-section, allowing you to identify both the internal jugular vein and the common carotid artery.

Whichever view you select, you should attempt to locate the tip of the needle in relation to the ultrasound beam and the internal jugular vein. This is especially important when you are viewing the structures in cross-section, since the needle will appear only as a dot on the screen, which makes it difficult to determine the exact location of the tip.⁶

PROCEDURE

Evaluate the potential placement site with ultrasonography before establishing a sterile field. Confirm that the proposed vein is patent by ensuring that it is compressible. After you have identified an acceptable site for cannulation, you will need an assistant.

Because performing a procedure that provides central venous access carries the risk of infection, universal precautions should be observed in placing a central catheter. Once the patient is positioned, prepare the skin using a chlorhexidine-based antiseptic and cover the area with a sterile, fenestrated drape. If the patient is not receiving general anesthesia, anesthetize the insertion site with 1% or 2% lidocaine.

To prepare the ultrasound probe, have the assistant, who does not need to be dressed in sterile garb, dispense enough acoustic gel into a sterile transducer sheath to cover the transducer surface inside the sheath. Have the assistant carefully feed the probe into the sheath and through the gel while extending the sterile sheath away from you along the length of the probe wire. Use sterile rubber bands or plastic clips to secure the sheath around the transducer. To complete acoustic coupling, apply a small amount of sterile ultrasound gel to the covered ultrasound probe or to the patient's skin. Because the sterile ultrasound probe is used intermittently throughout the procedure, identify a convenient sterile area on which the probe can be placed when it is not in use.

There are a variety of techniques and insertion points for internal jugular vein cannulation. The most common are the anterior, central, and posterior approaches. This supplement and the accompanying video address the use of ultrasound guidance as applied to the central approach, in which the needle is inserted between the two heads of the sternocleidomastoid muscle for internal jugular cannulation.

Position the transducer so that the internal jugular vein is centered in the resulting ultrasound image and between the two heads of the sternocleidomastoid muscle. Gently palpate the skin to confirm that the puncture will be between the muscle heads and not through one of the heads. With an 18-gauge needle, puncture the skin at the center of the transducer, being careful not to damage the sterile sheath. Advance the needle at a 45-degree angle; maintain negative pressure in the syringe until the vein is punctured.

When the needle passes caudally underneath the transducer, the needle, as well as soft-tissue tenting, can be viewed on the ultrasound screen. After the needle has penetrated the tissues, short "in and out" or "tapping" movements may help you to visualize the trajectory of the needle. In addition, the location of the needle tip

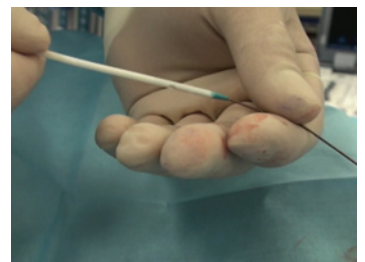


Figure 4. Insertion of Guidewire through Catheter.

REFERENCES

1. Karakitsos D, Labropoulos N, De Groot E, et al. Real-time ultrasound-guided catheterisation of the internal jugular vein: a prospective comparison with the landmark technique in critical care patients. *Crit Care* 2006;10:R162.
2. Hind D, Calvert N, McWilliams R, et al. Ultrasonic locating devices for central venous cannulation: meta-analysis. *BMJ* 2003;327:361.
3. Troianos C, Kuwik RJ, Pasquai JR, Lim AJ, Odasso DP. Internal jugular vein and carotid artery anatomy relation as determined by ultrasonography. *Anesthesiology* 1996;85:43-8.
4. Wang R, Snoey ER, Clements RC, Hern HG, Price D. Effect of head rotation on vascular anatomy of the neck: an ultrasound study. *J Emerg Med* 2006;31:283-6.
5. Calvert N, Hind D, McWilliams R, Davidson A, Beverley CA, Thomas SM. Ultrasound for central venous cannulation: economic evaluation of cost-effectiveness. *Anaesthesia* 2004;59:1116-20.
6. Chapman GA, Johnson D, Bodenham AR. Visualisation of needle position using ultrasonography. *Anaesthesia* 2006;61:148-58.
7. French J LH, Raine-Fenning NJ, Hardman JG, Bedford NM. Pitfalls of ultrasound guided vascular access: the use of three/four-dimensional ultrasound. *Anaesthesia* 2008;63:806-13.

Copyright © 2010 Massachusetts Medical Society.

may be visualized by tilting the transducer back and forth or by withdrawing the needle and realigning it.⁶ However, because the ultrasound image does not necessarily confirm the location of the tip, look in the syringe for aspiration of blood.

As soon as blood is freely aspirated, place the probe in the predetermined sterile location, stabilize the needle, and disconnect the syringe. Confirm that the blood flow is nonpulsatile. Bright-red, pulsatile blood is suggestive of arterial puncture; however, dark, nonpulsatile blood does not rule out arterial puncture. Using the Seldinger technique, introduce a flexible guidewire through the needle and into the vein. While holding the guidewire in place, remove the needle. At this point, the guidewire within the lumen of the vein can be visualized on the screen in both cross-sectional and longitudinal views. If you have any doubt about the location of the wire you can transduce the blood pressure by advancing a small catheter over the wire, removing the wire, and connecting the catheter to a transducer. Once the possibility of arterial cannulation is ruled out, reinsert the guidewire through the catheter and remove the catheter while leaving the guidewire in place.

Use a scalpel to make a small incision in the skin to widen the opening. Thread the guidewire through the distal opening of a dilator until it exits through the proximal end of the dilator. Confirm that it has reached the proximal end of the dilator, hold the wire in place, and advance the dilator through the skin and into the vessel. While holding the guidewire in place, remove the dilator. Insert the guidewire through the distal opening of the central venous catheter until it exits through the proximal end of the catheter (Fig. 4). Secure the proximal end of the wire to prevent inadvertent advancement into the vessel, then advance the catheter into the vein. Use ultrasonography to verify that the catheter is properly placed within the lumen of the vessel. Once proper placement is achieved, remove the guidewire and anchor the catheter to the skin with sutures. Each port should be flushed with saline solution and fluids administered as needed. Obtain a chest radiograph to confirm proper placement of the catheter.

COMPLICATIONS

Cannulation of the internal jugular vein is an invasive procedure that can result in infection, air embolism, or death. Complications from mechanical injury include carotid-artery puncture, skin hematoma, pneumothorax, hemothorax, and catheter misplacement.

SUMMARY

Although ultrasound guidance is the recommended technique for internal jugular vein cannulation, complications may occur.⁷ Ultrasound-guided internal jugular vein cannulation should be considered complementary to the landmark technique, and its success depends on the provider's skill, understanding of ultrasound technique and function, and knowledge of neck anatomy. Proper use of ultrasonography can substantially minimize potential complications, reduce the time required to complete the procedure, and facilitate proper catheter placement.

Disclosure forms provided by the authors are available with the full text of this article at NEJM.org.